

Shimon Rochkind, M.D.
Specialist in Neurosurgery and Microsurgery

November 25, 2013

To whom it may concern,

Re: Miron Mironenko
DOB: 09.12.2012

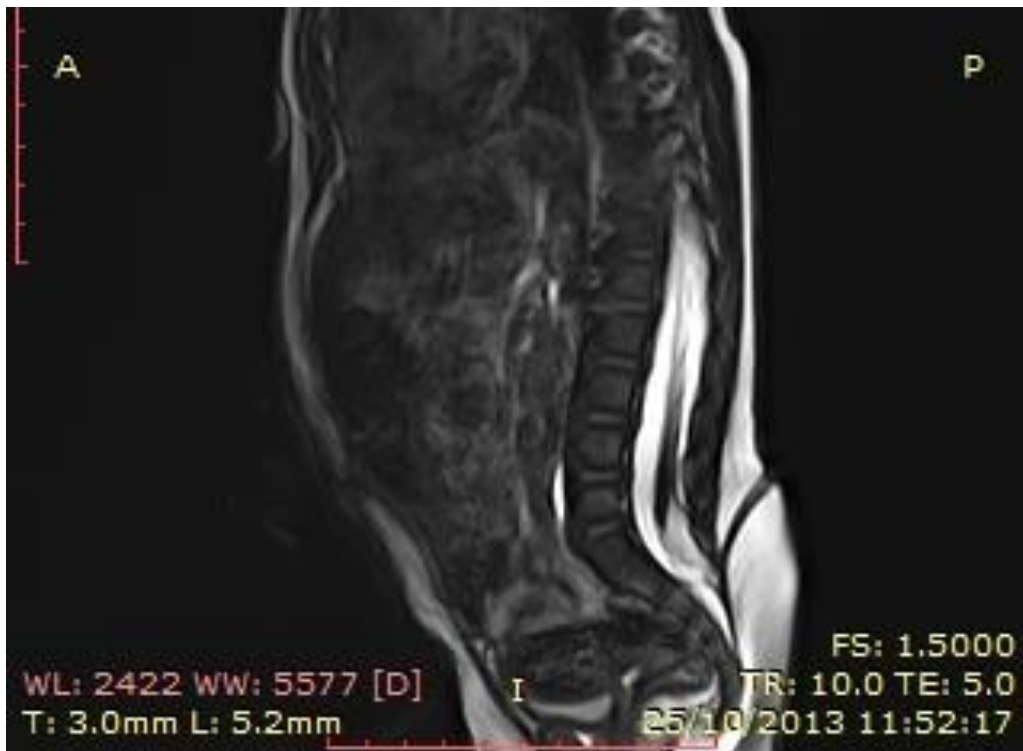Diagnosis:

Spina bifida
Dorsal caudal lipoma
Tethered spinal cord syndrome
Dermal sinus

Urinary and bowel disturbances

MRI 25.10.13:

Tethered spinal cord. Dermal sinus. Dorsal caudal lipoma.



Shimon Rochkind, M.D.

Specialist in Neurosurgery and Microsurgery

Recommendations:

Based on the clinical and neuro-radiological picture, surgical intervention was recommended. The surgery will be performed in 2 parts: neurosurgical part and plastic surgery part. During the surgery will be performed:

I – Neurosurgical part:

Removal of the fibrous-fat scar tissue, dermal sinus, and dorsal lipoma.
Microsurgical release and neurolysis of the cauda equine nerve roots.
Release and untethering of the spinal cord.
Dural canal reconstruction, if necessary using Neuro patch.


II – Plastic surgery part:

Spinal canal reconstruction: Paravertebral muscle flaps. Paravertebral fascia turnover.

The surgery will be performed with intraoperative electrophysiological monitoring: spinal cord evoked-response, motor evoked response, somato-sensory evoked response and compound muscle action potential, including anal sphincter.

The surgical team will include: specialist in neurosurgery, specialist in plastic surgery, specialist in neurophysiology, pediatric anesthesiologist and surgical assistant.

Sincerely yours,

A handwritten signature in black ink, appearing to read 'S. Rochkind', enclosed within a large, loopy, handwritten flourish that underlines the signature.

Dr. Shimon Rochkind
Specialist in Neurosurgery and Microsurgery